

Available online at www.sciencedirect.com

SCIENCE @ DIRECT®

Psychiatry Research: Neuroimaging xx (2006) xxx–xxx

PSYCHIATRY
RESEARCH
NEUROIMAGING

www.elsevier.com/locate/psychresns

Detection and mapping of hippocampal abnormalities in autism

Rob Nicolson^{a,*}, Timothy J. DeVito^b, Christine N. Vidal^c, Yihong Sui^c,
Kiralee M. Hayashi^c, Dick J. Drost^b, Peter C. Williamson^a, Nagalingam Rajakumar^a,
Arthur W. Toga^c, Paul M. Thompson^c

^a*Department of Psychiatry, The University of Western Ontario, London, Ontario, Canada*^b*Department of Medical Biophysics, The University of Western Ontario, London, Ontario, Canada*^c*Laboratory of Neuro Imaging, Department of Neurology, UCLA School of Medicine, Los Angeles, CA, United States*

Received 7 September 2005; received in revised form 2 February 2006; accepted 13 February 2006

Abstract

Brain imaging studies of the hippocampus in autism have yielded inconsistent results. In this study, a computational mapping strategy was used to examine the three-dimensional profile of hippocampal abnormalities in a group of males with autism. Twenty-one males with autism (age: 9.5 ± 3.3 years) and 24 male controls (age: 10.3 ± 2.4 years) underwent a volumetric magnetic resonance imaging scan at 3-Tesla. The hippocampus was delineated, using an anatomical protocol, and hippocampal volumes were compared between the two groups. Hippocampal traces were also converted into three-dimensional parametric surface meshes, and statistical brain maps were created to visualize morphological differences in the shape and thickness of the hippocampus between groups. Parametric surface meshes and shape analysis revealed subtle differences between patients and controls, particularly in the right posterior hippocampus. These deficits were significant even though the groups did not differ significantly for traditional measures of hippocampal volume. These results suggest that autism may be associated with subtle regional reductions in the size of the hippocampus. The increased statistical and spatial power of computational mapping methods provided the ability to detect these differences which were not found with traditional volumetric methods.

© 2006 Published by Elsevier Ireland Ltd.

Keywords: Autism; Hippocampus; MRI

1. Introduction

Autism is a severe developmental disorder characterized by social deficits, impaired communication, and restricted and repetitive behavior patterns (American Psychiatric Association, 2000). There is strong evidence that autism is associated with abnormal brain develop-

ment, but the anatomical extent of these neurobiological abnormalities is unknown (Nicolson and Szatmari, 2003).

Abnormalities of the hippocampus and related limbic structures have been hypothesized to be relevant to the pathophysiology of autism because of their role in learning, social functioning, and emotion, functions that are typically disturbed in autism (Bauman and Kemper, 1985; DeLong, 1992; Bachevalier, 1994). One postmortem study reported that patients with autism had small, densely packed neurons in the CA1 through CA4 hippocampal fields and the subiculum as well as reduced complexity and extent of dendritic arborization in the CA1 and CA4 fields

* Corresponding author. London Health Sciences Centre, 800 Commissioners Road East, E2-601, London, Ontario, Canada N6C-2V5. Tel.: +1 519 685 8427; fax: +1 519 685 8595.

E-mail address: Rnicolso@uwo.ca (R. Nicolson).

(Bauman and Kemper, 1985; Raymond et al., 1996). However, other histopathological studies have failed to find similar hippocampal abnormalities (Bailey et al., 1998).

To date, anatomic studies of the hippocampus in autism using magnetic resonance imaging (MRI) have yielded inconsistent results. Five studies have found no difference in size of the hippocampus between patients and controls (Saitoh et al., 1995; Piven et al., 1998; Haznedar et al., 2000; Howard et al., 2000; Bigler et al., 2003). Others reported a reduction in the ratio of hippocampal volume to total brain volume among patients with autism (Aylward et al., 1999), while still others have reported increased hippocampal size in the disorder (Sparks et al., 2002; Rojas et al., 2004; Schumann et al., 2004).

While factors related to subject selection may have contributed to this inconsistency, the neuroanatomic definition of the hippocampus may have also played a role. Previous studies have all assessed the hippocampus in autism using traditional volumetric methods, which can be insensitive to anatomical shape variability and unlikely to identify subtle regional differences in anatomy between groups. Recently, however, computational mapping methods have been developed to examine hippocampal structure. Unlike traditional volumetric methods, the use of surface mesh models and statistical maps permits the examination of highly localized group differences in hippocampal morphology while preserving subtle variability patterns within groups (Thompson et al., 2004a,b). Although this approach is complementary to voxel-based methods that assess differences in tissue types at each voxel of stereotaxic space, the shape-modeling approach works by averaging the geometry of the anatomical models rather than comparing segmented images. These computational methods have detected regional alterations of hippocampal morphology in conditions such as schizophrenia and depression, even in the absence of significant volume reductions (Csernansky et al., 2002; Posener et al., 2003; Narr et al., 2004).

The purpose of this study was to use computational mapping methods to detect and visualize hippocampal abnormalities in autism. We hypothesized that patients with autism would have localized hippocampal abnormalities, although the direction of the abnormalities (excess or atrophy) was not predicted in advance.

2. Methods

2.1. Subjects

Twenty-one males with autism between the ages of 6 and 16 participated in this study. The diagnosis of autism

was made using the Autism Diagnostic Interview-Revised (ADI-R; Lord et al., 1994), the Autism Diagnostic Observation Schedule (ADOS-G; Lord et al., 2000), and clinical observation. On the ADOS-G, one patient was assessed with module 1, three patients with module 2, 10 patients with module 3, and 7 patients with module 4. All patients met DSM-IV-TR criteria for autism (American Psychiatric Association, 2000) as well as ADI-R and ADOS-G algorithm criteria. Patients were also assessed using the Wechsler Intelligence Scale for Children, 3rd Edition (WISC-III) or the Leiter International Performance Scale. Exclusionary criteria for patients included a non-verbal IQ below 70 or a seizure disorder or any other neurological condition. All patients had a physical examination prior to participation in this study, including height, weight, and head circumference (defined as the maximal frontal–occipital circumference). Handedness was determined through clinical observation and the report of the patients and their parents. At the time of the scan, nine patients were being treated with psychotropic medication: six were taking stimulants, five were receiving dopamine antagonists, two were taking SSRIs, and one being treated with a cholinesterase inhibitor. Among the 12 patients who were not taking medications at the time of the study, seven were medication-naïve, four had discontinued their previous medications at least four weeks prior to the scan, and one subject being treated with a stimulant had discontinued it one week before his scan.

Twenty-four males between the ages of 6 and 16, drawn from the local community through advertisement and word of mouth, participated as control subjects. They were assessed with the Schedule for Affective Disorders and Schizophrenia-Childhood Version (Kaufman et al., 1997) to ensure that none had an axis I psychiatric disorder. Additionally, none had a personal history of neurological disorders or a family history of autism or mental retardation. Control subjects were also assessed with the WISC-III or the Wechsler Abbreviated Scale of Intelligence, and a full-scale IQ of less than 70 was exclusionary. Head circumference and handedness were determined in control subjects using the same method as in the patients.

This study was approved by the local Research Ethics Board. The parents or legal guardians of all subjects provided written consent for participation in this study, while the subjects provided written assent.

2.2. Magnetic resonance imaging

All subjects were scanned on a 3.0-Tesla head-only scanner (IMRIS, Winnipeg, Canada) with a quadrature head coil. All patient scans and the majority of control

143 subject scans were acquired during the evening. To
 144 facilitate completion of their scans, 14 patients with
 145 autism received sedation with oral midazolam.

146 Standard T1-weighted localizer images were acquired
 147 initially. Images used for volumetric analysis were then
 148 acquired using a T1-weighted 3-D MP-RAGE (Magnetiza-
 149 tion Prepared Rapid Gradient Echo) sequence (TI =
 150 200 ms, TR = 11 ms, TE = 5 ms, flip-angle = 12°, Field of
 151 View = 24 cm, total scan time: 8 min) with 1.2-mm
 152 isotropic voxels.

153 2.3. Image processing and analysis

154 Each brain volume was corrected for radio frequency
 155 field inhomogeneities (Sled et al., 1998) and resliced into a
 156 standard orientation. Twenty standard anatomical land-
 157 marks were identified by a trained operator (C.V.) in all
 158 three planes and matched with a set of corresponding point
 159 locations defined on the ICBM53 stereotaxic brain
 160 template (Mazziotta et al., 2001). As in previous studies
 161 (e.g., Thompson et al., 2004a), these landmarks were used
 162 to compute a three-translation and three-rotation rigid-
 163 body linear transformation for each brain volume to align it
 164 to the standardized coordinate system of the ICBM53
 165 average brain. Each brain volume was reoriented to correct
 166 for head alignment and resampled to 1.0 mm isotropic
 167 voxels using trilinear interpolation and a 6-parameter
 168 Procrustes fit. In addition, a second set of analyses were
 169 performed to adjust the data for overall differences in brain
 170 scale. To do this, each brain was uniformly scaled into the
 171 ICBM53 stereotaxic space using a 9-parameter linear
 172 transformation, allowing the brain to be scaled to match the
 173 standardized average brain template.

174 2.4. Hippocampal modeling

175 The hippocampi were digitized bilaterally by a single
 176 individual blind to subject data and hemisphere (data were
 177 randomly flipped in the midsagittal plane to avoid any
 178 possible bias). Anatomical segmentation was performed
 179 according to criteria adapted from the detailed protocol of
 180 Pantel et al. (2000), using a standard neuroanatomical atlas
 181 of the hippocampus (Duvernoy and Bourguoin, 1998).
 182 One rater (Y.S.) blind to group status traced the gray/white
 183 or gray/CSF interfaces separating the hippocampi from
 184 surrounding anatomy using interactive segmentation
 185 software (Woods, 2003). Boundaries were traced on the
 186 rigidly re-aligned gray scale brain volumes. The hippo-
 187 camp were traced in coronal brain slices from anterior to
 188 posterior and the digitized surface contours were displayed
 189 simultaneously in all three viewing planes to facilitate the
 190 accurate identification of neuroanatomic boundaries,

191 particularly that between the hippocampus and amygdala
 192 (see Fig. 1a). Contours were drawn on images magnified
 193 four-fold to allow subvoxel precision and faithful tracking
 194 of small-scale features. Hippocampal tracing in each
 195 hemisphere began at the indentation of the hippocampal
 196 sulcus, or when not visible, at the most medial point of the
 197 hippocampus in the coronal plane. The alveus was used as
 198 the superior boundary and the white matter of the
 199 parahippocampal gyrus as the inferior boundary. The
 200 inferior temporal horn of the lateral ventricle was used as
 201 the lateral boundary and the ambient cistern as the medial
 202 boundary. The subiculum was included in hippocampal
 203 tracings. As suggested by Pantel et al. (2000), the use of all
 204 three planes was critical to separating the hippocampus
 205 from the amygdala. The alveus, as viewed in three
 206 dimensions, was used as the border between the
 207 hippocampus and the amygdala anteriorly. The alveus
 208 itself was excluded from the measurement. In mid-anterior
 209 hippocampal regions, the invagination of the hippocampal
 210 sulcus was followed. Hippocampal outlines were contin-
 211 ued posteriorly until hippocampal gray matter formed an
 212 oval mass medial to the atrium of the lateral ventricles, but
 213 excluded the subsplenial gyrus. Volumes were obtained
 214 from the hippocampal surface tracings for use as
 215 dependent measures in statistical analyses. This method
 216 has previously shown high inter- and intra-rater reliability
 217 for hippocampal measurements (Thompson et al., 2004a).

218 2.5. Anatomical surface averaging

219 Anatomical mesh modeling methods were used to
 220 match equivalent hippocampal surface points, obtained
 221 from manual tracings, across subjects and groups. To
 222 match the digitized points representing the hippocampal
 223 surface traces in each brain volume, the manually
 224 derived contours were made spatially uniform by mo-
 225 deling them as a three-dimensional parametric surface
 226 mesh (see Fig. 1). These three-dimensional parametric
 227 surface models are indexed using two-dimensional
 228 parameter space. The anatomical mesh modeling pro-
 229 cedures allow the averaging of hippocampal surface
 230 morphology across all individuals belonging to a group
 231 and the recording of the amount of three-dimensional
 232 variation among homologous surface points relative to
 233 the group averages.

234 2.6. Surface distance mapping

235 The three-dimensional parametric mesh models of
 236 each individual's hippocampi were analyzed to estimate
 237 the regional specificity of hippocampal volume changes
 238 in autism. A “medial curve” was defined along the

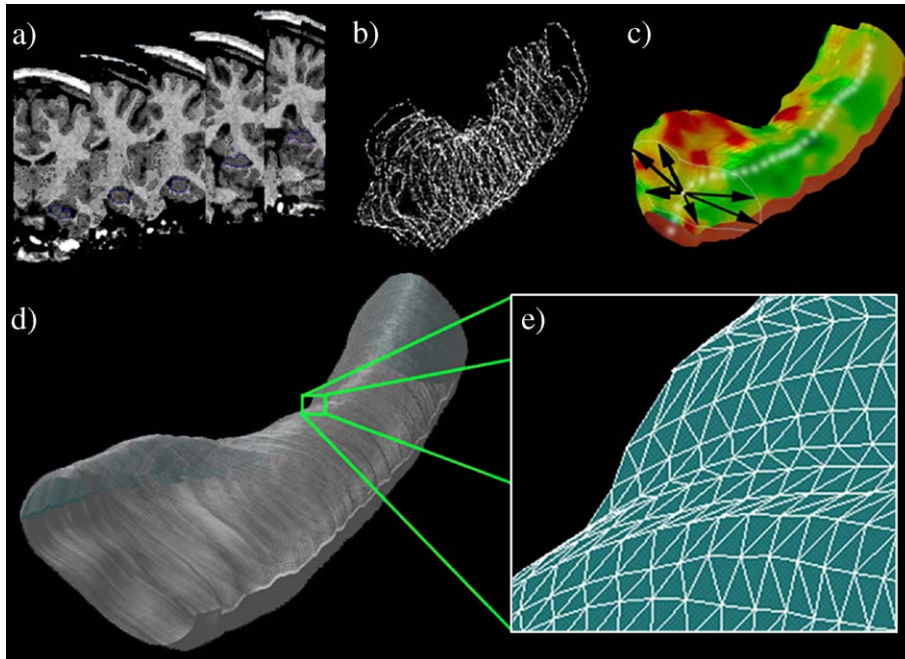


Fig. 1. Hippocampal surface modeling. Each individual's hippocampus is traced in coronal MRI sections (a) and converted to a mesh surface representation (b and c) in which the radial size of the hippocampus is measured from a centerline and plotted in color on the surface to index radial atrophy. Arrows in (c) represent vectors from the centerline to various points on the hippocampal surface. These meshes are averaged across subjects (d), and atrophy or expansion relative to the control mean is computed at each surface point (e).

239 anterior–posterior axis of the hippocampus in stereo-
 240 taxic coordinate space and the radial size of each
 241 hippocampus at each boundary point was assessed by
 242 measuring the radial distances from homologous
 243 hippocampal surface points to the central core of the
 244 individual's hippocampal surface model (Fig. 1c) (Narr
 245 et al., 2004; Thompson et al., 2004a). Since radial
 246 distances from the medial core to the surface boundary
 247 are measured at thousands of points along the surface,
 248 the resulting radial distance maps detect nonuniform
 249 volumetric changes on a very local scale and may be
 250 compared statistically between groups at equivalent
 251 hippocampal surface points.

252 2.7. Statistical analysis

253 Age, race, handedness, height, head circumference,
 254 the scaling factor needed to transform each brain volume
 255 into stereotaxic space, and intelligence quotient (verbal,
 256 non-verbal, and full-scale) were compared using *t*-tests
 257 or chi-square analyses.

258 Thickness measures improve the localization of
 259 deficits but may be less sensitive to differences in the
 260 length of the hippocampus. Traditional volumetric mea-
 261 sures may thus be more sensitive than thickness maps
 262 for detecting group differences in some instances, while

thickness maps may be more sensitive in others. 263
 Therefore, we used both traditional volumetric methods 264
 and statistical maps in order to compare the ability of 265
 both methods to detect hippocampal abnormalities 266
 among patients with autism. 267

Right and left hippocampal volumes measured using 268
 traditional volumetric methods were compared between 269
 groups using Analysis of Variance, with group as the 270
 between subjects factor. This analysis was applied to 271
 both the raw and scaled hippocampal volumes (i.e., both 272
 before and after controlling for group differences in 273
 brain size through scaling; see section on brain size 274
 correction below). 275

To evaluate regional differences in hippocampal 276
 volume as indexed by measures of hippocampal radial 277
 distance, Student's *t*-tests were performed at equivalent 278
 locations on the hippocampal surface maps. Uncorrected *t* 279
 values and their corresponding two-tailed probability 280
 values were mapped onto the averaged hippocampal sur- 281
 face models of the entire group and displayed in three 282
 dimensions in scaled and raw space. 283

For tests of overall volume differences and for statistical 284
 mapping of surface-based measures, a two-tailed alpha 285
 level of $P < 0.05$ was used as the significance threshold. 286
 However, for statistical mapping, comparisons were made 287
 at thousands of hippocampal surface points. Permutation 288

289 testing was therefore used to confirm the overall
 290 significance of the statistical mapping results, adjusting
 291 for multiple comparisons. This accounts for the spatial
 292 autocorrelation of the residuals of the statistical model
 293 while adjusting for the multiple comparisons implicit in
 294 conducting multiple statistical tests at each point on a
 295 surface (Nichols and Holmes, 2002). Using a threshold of
 296 $P < 0.05$, uncorrected, the number of significant results
 297 between patients with autism and the control subjects in
 298 the actual data was compared to the number of significant
 299 results produced during the permutation testing to produce
 300 a corrected overall significance value for each map
 301 (Thompson et al., 2004c).

302 2.8. Brain size correction

303 For statistical mapping of hippocampal surface para-
 304 meters, image volumes and the hippocampal contours
 305 were mapped into stereotaxic space, adjusting for
 306 differences in brain size. However, uncertainty exists as
 307 to whether or not brain size corrections increase or
 308 decrease error variance for region of interest comparisons
 309 (Arndt et al., 1991; Mathalon et al., 1993). To allow for
 310 either possibility, we built the same anatomical maps and
 311 performed the same comparisons using raw (“descaled”)
 312 hippocampal volumes, which were derived by dividing
 313 each hippocampal volume by the scaling factor used to
 314 transform it to the ICBM53 average brain. To descale the
 315 three-dimensional maps created previously, the inverse of
 316 the global scaling transformation matrix was applied to the
 317 hippocampal surface points. A least squares rigid
 318 transform with 6 parameters (without scaling) was then
 319 applied to the resulting hippocampal traces to align them
 320 rigidly with the ICBM53 average brain dataset. Maps of
 321 group differences were created both before and after

adjusting for any individual and group differences in brain
 size.

3. Results

3.1. Subjects

The groups did not differ significantly in terms of
 age, race, height, head circumference, or the scaling
 factor used to transform each image volume into
 stereotaxic space (see Table 1). While there was no
 significant difference in non-verbal IQ between the two
 groups, patients did have a significantly lower verbal IQ
 ($P = 0.0003$) and full-scale IQ ($P = 0.007$). Consistent
 with previous studies (Escalante-Mead et al., 2003),
 there was a significantly greater proportion of left-
 handed subjects in the patient group ($P = 0.007$). Mean
 ADI-R algorithm scores for subjects in the autism group
 are presented in Table 2.

3.2. Hippocampal volume

Using traditional volumetric methods, patients with
 autism did not differ significantly from controls in the
 volume of the individual hippocampi or the combined
 hippocampal volume (see Table 3). The pattern of
 results was similar when either the descaled (native
 space) images were used or when differences in brain
 size were controlled for through the use of the scaled
 images.

3.3. Hippocampal distance maps

Permutation tests on the descaled (native space) maps
 of the hippocampi did not reveal any regions with

t1.1 Table 1
 t1.2 Demographic characteristics of patients with autistic disorder and control subjects

t1.3 Measures	Patients ($n = 21$)	Control subjects ($n = 24$)	Test statistic	df	P
t1.4 Age (years)	9.5 ± 3.3	10.3 ± 2.4	$t = 1.0$	43	0.9
t1.5 Race (# Caucasian)	20	24	$\chi^2 = 1.2$	1	0.3
t1.6 Handedness (R:L)	15:6	24:0	$\chi^2 = 7.9$	1	0.007
t1.7 Height (cm)	145.1 ± 19.7	145.1 ± 13.3	$t = 0.01$	38	0.9
t1.8 Head circumference (cm)	55.3 ± 2.6	54.8 ± 1.8	$t = 0.6$	43	0.5
t1.9 Image scaling factor ^a	1.3 ± 0.1	1.4 ± 0.1	$t = 0.6$	43	0.5
t1.10 Verbal IQ	90.9 ± 11.3	106.3 ± 11.3	$t = 4.0$	35	0.0003
t1.11 Non-verbal IQ	98.3 ± 14.2	104.4 ± 14.6	$t = 1.4$	41	0.2
t1.12 Full-scale IQ	93.8 ± 11.9	105.4 ± 12.1	$t = 2.8$	35	0.007

All continuous data presented as mean ± standard deviation. Note that degrees of freedom vary across tests due to missing data for some subjects,
 including the lack of a verbal or full-scale IQ for subjects tested using the Leiter International Performance Scale.

^a The Image Scaling Factor refers to the scaling factor used to transform each image volume into stereotaxic space.

t2.1 Table 2
Autism Diagnostic Interview-Revised (ADI-R) algorithm scores for subjects with autism ($n=21$)

t2.3 Domain	Score
t2.4 Social interactions	22.5±5.4
t2.5 Communication	
t2.6 Verbal subjects ($n=20$)	15.8±3.7
t2.7 Non-verbal subjects ($n=1$)	14.0
t2.8 Restricted and repetitive behavior	4.2±1.0

t2.9 All continuous data presented as mean±standard deviation.

350 significant group differences (see Fig. 2). Small regions
351 of volume excess in autism (red colors, Fig. 2(a) and (c))
352 were visible in the anterior hippocampus, but these
353 changes were not significant when permutation testing
354 was performed.

355 However, when total brain size was controlled for
356 through the use of the scaled maps, significance maps
357 (Fig. 3) revealed several localized group differences.
358 Patients with autism had a significant reduction in
359 hippocampal volume in the right medial posterior
360 hippocampus (Fig. 3b, red color and white color) and
361 a regional increase in thickness in the right medial
362 anterior hippocampus (Fig. 3c, red color). Permutation
363 tests on these specific regions of interest to control for
364 multiple testing confirmed the significant reduction in
365 the right medial posterior hippocampus of patients with
366 autism ($P=0.02$), but the increase in the right medial
367 anterior hippocampus among patients did not reach
368 significance. There were no significant group differ-
369 ences in the left hippocampus.

370 4. Discussion

371 To our knowledge, this is the first study to use com-
372 putational mapping methods to investigate hippocampal
373 abnormalities in autism. While traditional methods did not
374 reveal any significant group differences in total hippo-
375 campal volume, computational methods revealed a loca-

lized reduction in volume of the right medial posterior
hippocampus in patients with autism after controlling for
total brain size. This volume reduction could be due to
specific abnormalities of the dentate gyrus, the hippo-
campal CA1 region, the CA3 region, or the CA4 region,
or a combination of these regions. Although the
methodology employed here is not able to determine
which of these regions contributes to the volumetric
deficit seen among patients, the three previous studies of
the posterior hippocampus have not detected significant
differences between patients and controls in the total
cross-sectional area of the subiculum and CA1 through
CA3 regions in patients with autism. (Saitoh et al., 1995,
2001; Bigler et al., 2003). Saitoh et al. (2001), however,
did report a reduction in cross-sectional area in the
combined CA4 and dentate gyrus (the area dentata).
While the other two studies of the posterior hippocampus
did not find significant reductions in the size of the area
dentata in autism, they both had smaller sample sizes and
also subdivided their patient groups by the presence or
absence of macrocephaly (Bigler et al., 2003) or the
presence or absence of mental retardation or seizures
(Saitoh et al., 1995), thereby further reducing the number
of subjects used in each comparison.

As noted previously, studies of the hippocampus in
patients with autism have yielded contradictory results.
This inconsistency may be due, at least in part, to factors
such as sample size, subject age and gender, specific
diagnosis (i.e., autism, Asperger's syndrome, or perva-
sive developmental disorder not otherwise specified),
and the presence or absence of mental retardation and
seizures. The neuroanatomic definition of the hippo-
campus may have also contributed to the inconsistency
seen in earlier studies. In contrast to the computational
mapping methods used here, previous studies of the
hippocampus in autism examined the total volume of the
hippocampus using traditional methods of analysis.
However, given the anatomical and functional differen-
ces of hippocampal subregions (Duvernoy and

t3.1 Table 3
t3.2 Hippocampal volume, with and without correction for brain size, in patients with autism and comparison subjects

t3.3 Measure ^a	Patients ($n=21$)	Comparison subjects ($n=24$)	F	df	P
t3.4 Native space					
t3.5 Left hippocampus	2654.2±348.7	2536.6±248.4	1.7	1,43	0.2
t3.6 Right hippocampus	2730.1±333.8	2680.6±289.5	0.3	1,43	0.6
t3.7 Total hippocampus	5384.3±657.3	5217.2±487.8	0.9	1,43	0.3
t3.8 Scaled					
t3.9 Left hippocampus	3533.2±411.0	3440.7±283.0	0.8	1,43	0.4
t3.10 Right hippocampus	3635.0±394.1	3640.0±383.6	0.1	1,43	0.9
t3.11 Total hippocampus	7168.2±773.5	7080.7±596.3	0.2	1,43	0.7

t3.12 ^a Hippocampal volumes given in mm³. All continuous data presented as mean±standard deviation.

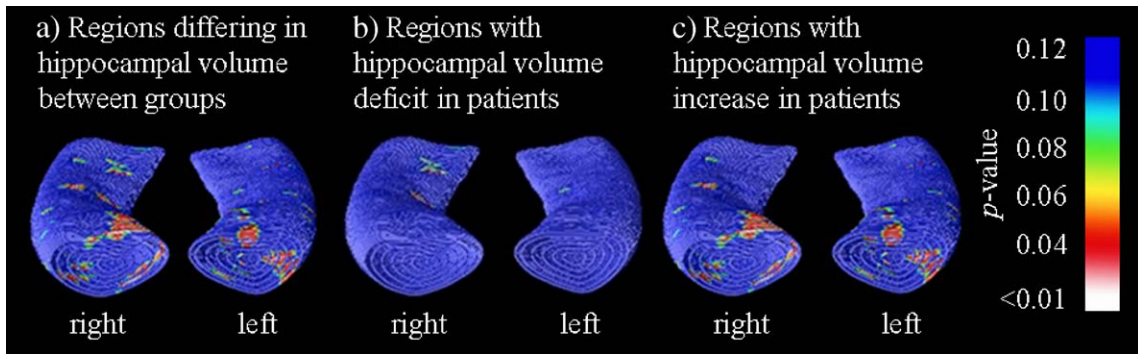


Fig. 2. Raw (descaled) hippocampal surface probability maps of patients with autism and controls, showing regions of overall differences between the groups (a), regions where patients had reductions in hippocampal volume relative to comparison subjects (b), and regions where patients had local increases in hippocampal volume relative to comparison subjects (c). While small regions of volume excess in autism were visible in the anterior hippocampus (red colors, (a) and (c)), these changes were not significant when permutation testing was performed to correct for multiple comparisons. (For interpretation of the references to colour in this figure legend, the reader is referred to the web version of this article.)

415 Bourgooin, 1998) as well as the limited diagnostic
 416 specificity afforded by traditional methods, such an
 417 approach may be less suitable than computational
 418 mapping methods. Computational maps, in conjunction
 419 with permutation testing, have more power than
 420 traditional volumetric measurements to detect group
 421 differences that are spatially heterogeneous and that do
 422 not affect the entire volume of a structure uniformly
 423 (Thompson et al., 2004b, 2005; Lin et al., 2005). As a
 424 result, subtle regional abnormalities may be detected
 425 with computational methods, even in the absence of
 426 global volumetric differences, as is the case in this study.
 427 The lower power of traditional volumetric measures
 428 may explain why studies using them have had
 429 inconsistent results, with many finding no significant
 430 group differences, as was noted here.

The spatial localization of volumetric abnormalities 431
 of the hippocampus provided by computational map- 432
 ping methods permits a greater insight into the 433
 hippocampal regions potentially involved in the patho- 434
 physiology of autism. Functional brain imaging studies 435
 have indicated the importance of the hippocampus in 436
 facial encoding and recall (Haxby et al., 1996; Critchley 437
 et al., 2000; Kircher et al., 2001; Gur et al., 2002;). In 438
 particular, the right posterior hippocampus, the region 439
 differing between patients and controls in the present 440
 study, has been noted to be activated during the en- 441
 coding and processing of facial emotions in adults 442
 without developmental disorders (Haxby et al., 1996; 443
 Critchley et al., 2000). The right hippocampus is also 444
 involved in self-recognition, a process that may be an 445
 index of self-awareness (Kircher et al., 2001). Similarly, 446

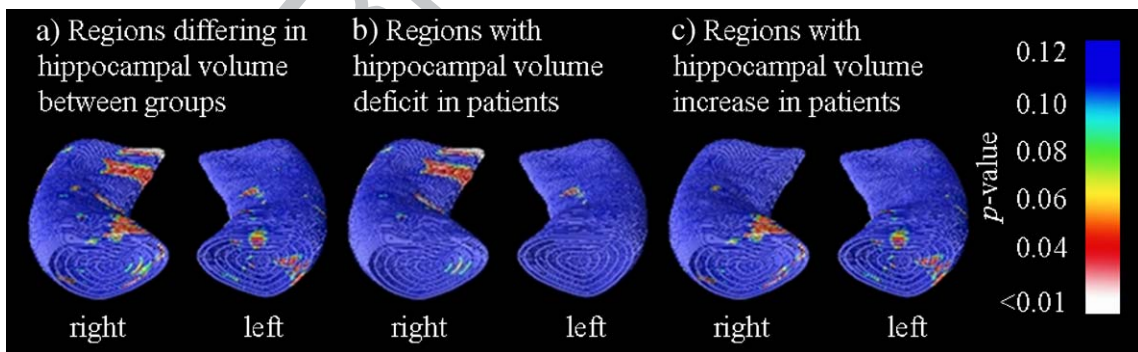


Fig. 3. Scaled hippocampal surface probability maps of patients with autism and controls, showing regions of overall differences between the groups (a), regions where patients showed reductions in hippocampal volume relative to comparison subjects (b), and regions where patients exhibited regional increases in hippocampal volume relative to healthy comparison subjects (c). Patients with autism showed a reduction in regional volume in the right medial posterior hippocampus (b) and an increase in regional volume in the right medial anterior hippocampus (c). When permutation testing was performed to correct for multiple comparisons, the only significant group difference was the reduction in regional volume in the right medial posterior hippocampus (red areas and white areas in (b)). (For interpretation of the references to colour in this figure legend, the reader is referred to the web version of this article.)

447 studies of single neuron activity have demonstrated
448 activity of the hippocampus during facial recognition
449 (Fried et al., 1997, 2002). The deficits of facial and
450 emotional processing and recall associated with autism
451 (Dawson et al., 2002) could thus reflect abnormalities of
452 the hippocampus.

453 In conjunction with other medial temporal lobe
454 structures, the regions of the posterior hippocampus
455 found to be smaller in patients with autism in this study
456 (the dentate gyrus and the CA1, CA3, and CA4 fields of
457 the hippocampus) are part of a neural circuit that is
458 essential to long-term memory formation and consoli-
459 dation (Squire et al., 2004). Abnormalities of the hippo-
460 campal components of this system, including the
461 regions differing between patients and controls in this
462 study, could disrupt the normal functioning of these
463 circuits and result in significant memory deficits (Squire
464 et al., 2004). While recent studies suggest aberrant spa-
465 tial working memory and episodic memory in patients
466 with autism (Salmond et al., 2005; Williams et al., in
467 press), some uncertainty remains about the precise
468 nature of memory abnormalities in autism (Tsatsanis,
469 2005). However, based upon the role of the hippocam-
470 pus in the integration, abstraction, and organization of
471 information constituting memories (Eichenbaum, 2000),
472 it has been proposed that the hippocampus is also critical
473 to relational memory processing. This process involves
474 the binding together of inputs to permit the establish-
475 ment of associations between items and events in a
476 memory and, thus, form a cohesive memory (Cohen
477 et al., 1999). Abnormalities of the hippocampus and its
478 connections with the prefrontal cortex could lead to
479 impairments in this process of “feature binding”, which
480 might be of relevance in understanding the aberrant
481 cognition seen in autism (Dawson et al., 2002). Frith
482 (1989) has suggested that autism is characterized by
483 “weak central coherence”, a reduction in the ability to
484 integrate information into a coherent and meaningful
485 whole. Aberrant hippocampal structure in autism, such
486 as that seen in this study, could lead to deficits in
487 relational memory processing and the ability to bind
488 features of various memories together and, ultimately, to
489 impairments in the ability to integrate information
490 appropriately.

491 In addition to identifying regional abnormalities of the
492 hippocampus potentially related to the pathophysiology of
493 autism, the spatial localization of volumetric differences by
494 computational mapping methods also provides important
495 information about the diagnostic specificity of these
496 hippocampal abnormalities. Studies using traditional
497 volumetric methods may also have limited diagnostic
498 specificity, in part, perhaps, because of the inability of

499 traditional methods to detect localized abnormalities. For
500 example, traditional morphometric methods have been
501 used to detect reductions in the total volume of the
502 hippocampus in many psychiatric illnesses, including
503 schizophrenia, depression, bipolar disorder, and post-trau-
504 matic stress disorder (Geuze et al., 2005). However, the
505 significantly enhanced spatial resolution of computational
506 mapping methods may provide further information about
507 the diagnostic specificity of hippocampal abnormalities.
508 Previous studies using this methodology have reported
509 localized volume reductions in the head of the hippo-
510 campus bilaterally and the left anterolateral hippocampus in
511 schizophrenia (Csernansky et al., 2002; Narr et al., 2004),
512 the subiculum in patients with depression (Posener et al.,
513 2003), the left lateral head of the hippocampus in Alzhei-
514 mer’s disease (Thompson et al., 2004a), and in the left
515 anterolateral hippocampus among methamphetamine abu-
516 sers (Thompson et al., 2004b). Additionally, a study of
517 patients with Tourette syndrome using methods similar to
518 those employed here reported an increase in the volume of
519 the dentate gyrus (Choi and Peterson, 2004). The reduction
520 in the right medial posterior hippocampus detected with
521 computational mapping methods in the present study
522 differs from the regions noted to be abnormal in these
523 studies of other neuropsychiatric disorders, suggesting that
524 it may be specific to autism.

525 The results of this study should be interpreted
526 cautiously due to several limitations including the small
527 sample size and the lack of female subjects. However,
528 given the known gender differences in prevalence and
529 severity of autism (Yeargin-Allsop et al., 2003), and in the
530 developmental trajectory of the hippocampus (Giedd et al.,
531 1996), the inclusion of males only in this study may have
532 highlighted group differences by removing gender vari-
533 ables affecting the size of the hippocampus. A number of
534 patients in the present study were taking psychotropic
535 medication, which could potentially have influenced the
536 results. However, studies of children and adolescents with
537 schizophrenia (Matsumoto et al., 2001) or bipolar disorder
538 (Frazier et al., 2005) have not detected significant
539 differences in hippocampal volume when patients who
540 were or were not receiving medication were compared. At
541 the same time, longitudinal studies of patients with
542 childhood-onset schizophrenia who were being treated
543 with antipsychotic medications have noted progressive
544 reductions in hippocampal volume relative to controls
545 (Giedd et al., 1999), although it is difficult to determine
546 whether these ongoing changes are due to medication or
547 are effects of the illness itself. Future studies with larger
548 samples will be required to delineate the effects of psycho-
549 tropic medications on the hippocampus in patients with
550 autism.

551 In this study, a computational mapping strategy was
 552 used to detect and visualize patterns of hippocampal
 553 thinning in children with autism, the greatest abnor-
 554 malities being noted in the right medial posterior
 555 hippocampus. Shape and computational mapping may
 556 reveal the spatial pattern of hippocampal deficits with
 557 greater visual and statistical power than traditional
 558 volumetric methods and may thus provide important
 559 insights into the timing of neurodevelopmental abnor-
 560 malities in autism as well as abnormal neural connec-
 561 tivity in the disorder. Future studies are required to
 562 confirm these differences in larger samples, and
 563 longitudinal studies will be needed to assess whether
 564 ongoing developmental changes in the hippocampus
 565 among patients with autism differ from those seen in
 566 typically developing children and adolescents.

567 Acknowledgement

568 Presented at the Annual Meeting of the American
 569 Academy of Child and Adolescent Psychiatry, Miami
 570 Beach, 2003. This work was supported by the Child and
 571 Parent Resource Institute and by grants from the Lon-
 572 don Health Sciences Research, Inc., the Ontario Mental
 573 Health Foundation, the Hospital for Sick Children Foun-
 574 dation (to R.N.), the National Institute for Biome-
 575 dical Imaging and Bioengineering, the National Center
 576 for Research Resources, and the National Institute on
 577 Aging (to P.T.: R21 EB01651, R21 RR019771, P50
 578 AG016570). Additional support was provided by grants
 579 PO1 EB001955, U54 RR021813, MO1 RR000865, and
 580 P41 RR13642 (to A.W.T.).

581 References

582 American Psychiatric Association, 2000. Diagnostic and Statistical
 583 Manual of Mental Disorders, 4th edition. American Psychiatric
 584 Association, Washington, D.C. Text Revision.
 585 Arndt, S., Cohen, G., Alliger, R.J., Swayze, V.W., 1991. Problems with
 586 ratio and proportion measures of imaged cerebral structures.
 587 *Psychiatry Research. Neuroimaging* 40, 79–89.
 588 Aylward, E.H., Minshew, N.J., Goldstein, G., Honeycutt, N.A.,
 589 Augustine, A.M., Yates, K.O., Barta, P.E., Pearson, G.D., 1999.
 590 MRI volumes of amygdala and hippocampus in non-mentally
 591 retarded autistic adolescents and adults. *Neurology* 53, 2145–2150.
 592 Bachevalier, J., 1994. Medial temporal lobe structures in autism: a
 593 review of experimental and clinical findings. *Neuropsychologia*
 594 32, 627–638.
 595 Bailey, A., Luthert, P., Dean, A., Harding, B., Janota, I., Montgomery,
 596 M., Rutter, M., Lantos, P., 1998. A clinicopathological study of
 597 autism. *Brain* 121, 889–905.
 598 Bauman, M.L., Kemper, T.L., 1985. Histoanatomic observations of the
 599 brain in early infantile autism. *Neurology* 35, 866–874.
 600 Bigler, E.D., Tate, D.F., Neeley, E.S., Wolfson, L.J., Miller, M.J.,
 601 Rice, S.A., Cleavinger, H., Anderson, C., Coon, H., Ozonoff, S.,

Johnson, M., Dinh, E., Lu, J., Mc Mahon, W., Lainhart, J.E., 2003. 602
 Temporal lobe, autism, and macrocephaly. *American Journal of* 603
Neuroradiology 24, 2066–2076. 604
 Choi, H.A., Peterson, B., 2004. Morphology of the amygdala and 605
 hippocampus in Tourette's Syndrome. Annual Meeting of the 606
 American Academy of Child and Adolescent Psychiatry, 607
 Washington. 608
 Cohen, N.J., Ryan, J., Hunt, C., Romine, L., Wszalek, T., Nash, C., 609
 1999. Hippocampal system and declarative (relational) memory: 610
 summarizing the data from functional neuroimaging studies. 611
Hippocampus 9, 83–98. 612
 Critchley, H., Daly, E., Phillips, M., Brammer, M., Bullmore, E., 613
 Williams, S., Van Amelsvoort, T., Robertson, D., David, A., 614
 Murphy, D., 2000. Explicit and implicit neural mechanisms for 615
 processing of social information from facial expressions: a 616
 functional magnetic resonance imaging study. *Human Brain* 617
Mapping 9, 93–105. 618
 Csernansky, J.G., Wang, L., Jones, D., Rastogi-Cruz, D., Posener, J.A., 619
 Heydebrand, G., Miller, J.P., Miller, M.I., 2002. Hippocampal 620
 deformities in schizophrenia characterized by high dimensional 621
 brain mapping. *American Journal of Psychiatry* 159, 2000–2006. 622
 Dawson, G., Webb, S., Schellenberg, G.D., Dager, S., Friedman, S., 623
 Aylward, E., Richards, T., 2002. Defining the broader phenotype of 624
 autism: genetic, brain, and behavioral perspectives. *Development* 625
 and *Psychopathology* 14, 581–611. 626
 DeLong, G.R., 1992. Autism, amnesia, hippocampus, and learning. 627
Neuroscience and Biobehavioral Reviews 16, 63–70. 628
 Duvernoy, H.M., Bourgoin, P., 1998. *The Human Hippocampus:* 629
Functional Anatomy, Vascularization and Serial Sections with 630
MRI, 2nd edition. Springer, New York. 631
 Eichenbaum, H., 2000. A cortical-hippocampal system for declarative 632
 memory. *Nature Reviews. Neuroscience* 1, 41–50. 633
 Escalante-Mead, P.R., Minshew, N.J., Sweeney, J.A., 2003. Abnormal 634
 brain lateralization in high-functioning autism. *Journal of* 635
Autism and Developmental Disorders 33, 539–543. 636
 Frazier, J.A., Chiu, S., Breeze, J.L., Makris, N., Lange, N., Kennedy, 637
 D.N., Herbert, M.R., Bent, E.K., Koner, V.K., Dieterich, M.E., 638
 Hodge, S.M., Rauch, S.L., Grant, P.E., Cohen, B.M., Seidman, L.J., 639
 Caviness, V.S., Biederman, J., 2005. Structural brain magnetic 640
 resonance imaging of limbic and thalamic volumes in pediatric 641
 bipolar disorder. *American Journal of Psychiatry* 162, 1256–1265. 642
 Fried, I., MacDonald, K.A., Wilson, C.L., 1997. Single neuron activity 643
 in human hippocampus and amygdala during recognition of faces 644
 and objects. *Neuron* 18, 753–765. 645
 Fried, I., Cameron, K.A., Yashar, S., Fong, R., Morrow, J.W., 2002. 646
 Inhibitory and excitatory responses of single neurons in the human 647
 medial temporal lobe during recognition of faces and objects. 648
Cerebral Cortex 12, 575–584. 649
 Frith, U., 1989. *Autism: Explaining the Enigma*. Blackwell, Oxford. 650
 Geuze, E., Vermetten, E., Bremner, J.D., 2005. MR-based in vivo 651
 hippocampal volumetrics: 2. Findings in neuropsychiatric dis- 652
 orders. *Molecular Psychiatry* 10, 160–184. 653
 Giedd, J.N., Vaituzis, A.C., Hamburger, S.D., Lange, N., Rajapakse, 654
 J.C., Kaysen, D., Vauss, Y.C., Rapoport, J.L., 1996. Quantitative 655
 MRI of the temporal lobe, amygdala, and hippocampus in normal 656
 human development: ages 4–18 years. *Journal of Comparative* 657
Neurology 366, 223–230. 658
 Giedd, J.N., Jeffries, N.O., Blumenthal, J., Castellanos, F.X., Vaituzis, A.C., 659
 Fernandez, T., Hamburger, S.D., Liu, H., Nelson, J., Bedwell, J., 660
 Tran, L., Lelane, M., Nicolson, R., Rapoport, J.L., 1999. Childhood- 661
 onset schizophrenia: progressive brain changes during adolescence. 662
Biological Psychiatry 46, 892–898. 663

- 664 Gur, R.C., Schroeder, L., Turner, T., McGrath, C., Chan, R.M.,
665 Turetsky, B.I., Alsup, D., Maldjian, J., Gur, R.E., 2002. Brain
666 activation during facial emotion processing. *NeuroImage* 16,
667 651–662.
- 668 Haxby, J.V., Ungerleider, L.G., Horwitz, B., Maisog, J.M., Rapoport,
669 J.I., Grady, C.L., 1996. Face encoding and recognition in the
670 human brain. *Proceedings of the National Academy of Sciences of*
671 *the United States of America* 93, 922–927.
- 672 Haznedar, M.M., Buchsbaum, M.S., Wei, T.C., Hof, P.R., Cartwright,
673 C., Bienstock, C.A., Hollander, E., 2000. Limbic circuitry in
674 patients with autism spectrum disorders studied with positron
675 emission tomography and magnetic resonance imaging. *American*
676 *Journal of Psychiatry* 157, 1994–2001.
- 677 Howard, M.A., Cowell, P.E., Boucher, J., Brooks, P., Mayes, A.,
678 Farrant, A., Roberts, N., 2000. Convergent neuroanatomical and
679 behavioural evidence of an amygdala hypothesis of autism. *Neuroreport* 11, 2931–2935.
- 680 Kaufman, J., Birmaher, B., Brent, D., Rao, U., Flynn, C., Moreci, P.,
681 Williamson, D., Ryan, N., 1997. Schedule for affective disorders
682 and schizophrenia for school-age children-present and lifetime
683 version (K-SADS-PL): initial reliability and validity data. *Journal*
684 *of the American Academy of Child and Adolescent Psychiatry* 36,
685 980–988.
- 686 Kircher, T.J., Senior, C., Phillips, M.L., Rabe-Hesketh, S., Benson, P.J.,
687 Bullmore, E.T., Brammer, M., Simmons, A., Bartels, M., David, A.S.,
688 2001. Recognizing one's own face. *Cognition* 78, B1–B15.
- 689 Lin, J.J., Salamon, N., Lee, A.D., Dutton, R.A., Geaga, J.A., Hayashi,
690 K.M., Luders, E., Toga, A.W., Engel, J., Thompson, P.M., 2005.
691 Mapping reduced cortical thickness and complexity in mesial
692 temporal lobe epilepsy with hippocampal sclerosis. *Annual*
693 *Meeting of the Organization for Human Brain Mapping, Toronto,*
694 *Canada.*
- 695 Lord, C., Rutter, M., Le Couteur, A., 1994. Autism diagnostic
696 interview-revised: a revised version of a diagnostic interview for
697 caregivers of individuals with possible pervasive developmental
698 disorders. *Journal of Autism and Developmental Disorders* 24,
699 659–685.
- 700 Lord, C., Risi, S., Lambrecht, L., Cook Jr., E.H., Leventhal, B.L.,
701 DiLavore, P.C., Pickles, A., Rutter, M., 2000. The autism diagnostic
702 observation schedule-generic: a standard measure of social and
703 communication deficits associated with the spectrum of autism.
704 *Journal of Autism and Developmental Disorders* 30, 205–223.
- 705 Mathalon, D.H., Sullivan, E.V., Rawles, J.M., Pfefferbaum, A., 1993.
706 Correction for head size in brain-imaging measurements. *Psychiatry*
707 *Research: Neuroimaging* 50, 121–139.
- 708 Matsumoto, H., Simmons, A., Williams, S., Pipe, R., Murray, R., Frangou,
709 S., 2001. Structural magnetic imaging of the hippocampus in early
710 onset schizophrenia. *Biological Psychiatry* 49, 824–831.
- 711 Mazziotta, J., Toga, A., Evans, A., Fox, P., Lancaster, J., Zilles, K., Woods,
712 R., Paus, T., Simpson, G., Pike, B., Holmes, C., Collins, L.,
713 Thompson, P., MacDonald, D., Iacoboni, M., Schormann, T., Amunts,
714 K., Palomero-Gallagher, N., Geyer, S., Parsons, L., Narr, K., Kabani,
715 N., Le Goualher, G., Boomsma, D., Cannon, T., Kawashima, R.,
716 Mazoyer, B., 2001. A probabilistic atlas and reference system for the
717 human brain: International Consortium for Brain Mapping (ICBM).
718 *Philosophical Transactions of the Royal Society of London. Series B,*
719 *Biological Sciences* 356, 1293–1322.
- 720 Narr, K.L., Thompson, P.M., Szeszko, P., Robinson, D., Jang, S.,
721 Woods, R.P., Kim, S., Hayashi, K.M., Asuncion, D., Toga, A.W.,
722 Bilder, R.M., 2004. Regional specificity of hippocampal volume
723 reductions in first-episode schizophrenia. *NeuroImage* 21,
724 1563–1575.
- Nichols, T.E., Holmes, A.P., 2002. Nonparametric permutation tests
726 for functional neuroimaging: a primer with examples. *Human*
727 *Brain Mapping* 15, 1–25.
- Nicolson, R., Szatmari, P., 2003. Genetic and neurodevelopmental
729 influences in autistic disorder. *Canadian Journal of Psychiatry* 48,
730 526–537.
- Pantel, J., O'Leary, D.S., Cretsingher, K., Bockholt, H.J., Keefe, H.,
732 Magnotta, V.A., Andreasen, N.C., 2000. A new method for the in
733 vivo volumetric measurement of the human hippocampus with
734 high neuroanatomical accuracy. *Hippocampus* 10, 752–758.
- Piven, J., Bailey, J., Ranson, B.J., Arndt, S., 1998. No difference in
736 hippocampus volume detected on magnetic resonance imaging in
737 autistic individuals. *Journal of Autism and Developmental*
738 *Disorders* 28, 105–110.
- Posener, J.A., Wang, L., Price, J.L., Gado, M.H., Province, M.A.,
740 Miller, M.I., Babb, C.M., Csermansky, J.G., 2003. High-dimen-
741 sional mapping of the hippocampus in depression. *American*
742 *Journal of Psychiatry* 160, 83–89.
- Raymond, G.V., Bauman, M.L., Kemper, T.L., 1996. Hippocampus in
744 autism: a Golgi analysis. *Acta Neuropathologica* 91, 117–119.
- Rojas, D.C., Smith, J.A., Benkers, T.L., Camou, S.L., Reite, M.L.,
746 Rogers, S.J., 2004. Hippocampus and amygdala volumes in
747 parents of children with autistic disorder. *American Journal of*
748 *Psychiatry* 161, 2038–2044.
- Saitoh, O., Courchesne, E., Egaas, B., Lincoln, A.J., Schreibman, L.,
750 1995. Cross-sectional area of the hippocampus in autistic patients
751 with cerebellar and corpus callosum abnormalities. *Neurology* 45,
752 317–324.
- Saitoh, O., Karns, C., Courchesne, E., 2001. Development of the
754 hippocampal formation from 2 to 42 years: MRI evidence of
755 smaller area. *Brain* 124, 1317–1324.
- Salmond, C.H., Ashburner, J., Connelly, A., Friston, K.J., Gadian, D.G.,
757 Vargha-Khadem, F., 2005. The role of the medial temporal lobe in
758 autistic spectrum disorders. *European Journal of Neuroscience* 22,
759 764–772.
- Schumann, C.M., Hamstra, J., Goodlin-Jones, B.L., Lotspeich, L.J.,
761 Kwon, H., Buonocone, M.H., Lammers, C.R., Reiss, A.L., Amaral,
762 D.G., 2004. The amygdala is enlarged in children but not
763 adolescents with autism; the hippocampus is enlarged at all ages.
764 *Journal of Neuroscience* 24, 6392–6401.
- Sled, J.G., Zijdenbos, A.P., Evans, A.C., 1998. A non-parametric
766 method for automatic correction of intensity non-uniformity in
767 MRI data. *IEEE Transactions on Medical Imaging* 17, 87–97.
- Sparks, B.F., Friedman, S.D., Shaw, D.W., Aylward, E.H., Echelard,
769 D., Artru, A.A., Maravilla, K.R., Giedd, J.N., Munson, J., Dawson,
770 G., Dager, S.R., 2002. Brain structural abnormalities in young
771 children with autism spectrum disorder. *Neurology* 59, 184–192.
- Squire, L.R., Stark, C.E., Clark, R.E., 2004. The medial temporal lobe.
773 *Annual Review of Neuroscience* 27, 279–306.
- Thompson, P.M., Hayashi, K.M., De Zubicaray, G.I., Janke, A.L., Rose,
775 S.E., Semple, J., Hong, M.S., Herman, D.H., Gravano, D., Doddrell,
776 D.M., Toga, A.W., 2004a. Mapping hippocampal and ventricular
777 change in Alzheimer disease. *NeuroImage* 22, 1754–1766.
- Thompson, P.M., Hayashi, K.M., Simon, S.L., Geaga, J.A., Hong, M.S.,
779 Sui, Y., Lee, J.Y., Toga, A.W., Ling, W., London, E.D., 2004b.
780 Structural abnormalities in the brains of human subjects who use
781 methamphetamine. *Journal of Neuroscience* 24, 6028–6036.
- Thompson, P.M., Lee, A.D., Dutton, R.A., Geaga, J.A., Hayashi, K.M.,
783 Eckert, M.A., Bellugi, U., Galaburda, A.M., Korenberg, J.R., Mills,
784 D.L., Toga, A.W., Reiss, A.L., 2005. Abnormal cortical complexity
785 and thickness profiles mapped in Williams Syndrome. *Journal of*
786 *Neuroscience* 25, 4146–4158.

- 788 Tsatsanis, K.D., 2005. Neuropsychological characteristics in autism
789 and related conditions. In: Volkmar, F.R., Paul, R., Klin, A.,
790 Cohen, D. (Eds.), *Handbook of Autism and Pervasive Develop-*
791 *mental Disorders*, Third edition. John Wiley and Sons, Inc.,
792 Hoboken, pp. 365–381.
- 793 Williams, D.L., Goldstein, G., Carpenter, P.A., Minshew, N.J., in
794 press. Verbal and spatial working memory in autism. *Journal of*
795 *Autism and Developmental Disorders*.
- 803
- Woods, R.P., 2003. Multitracer: a java-based tool for anatomic
796 delineation of grayscale volumetric images. *NeuroImage* 19,
797 1829–1834.
- 798
799 Yeargin-Allsop, M., Rice, C., Karapurkar, T., Doernber, N., Boyle, C.,
800 Murphy, C., 2003. Prevalence of autism in a US metropolitan area.
801 *Journal of the American Medical Association* 289, 48–55.
802

UNCORRECTED PROOF